

FACIAL INJURY IN A COLLEGIATE SOCCER PLAYER

Stacey Bonanno; Ron Ogradowicz, MPT, ATC, CSCS;
Susan A. Norkus, PhD, ATC

Quinnipiac University - Hamden, CT

HISTORY AND MECHANISM

A 19 year old male soccer player sustained an injury to the right side of his face inferior to his right orbit. During practice, the athlete had jumped up in the air in an attempt to win a head-ball, when he received a blow to his right orbit/zygomatic arch from his teammate's elbow. The athlete immediately fell to the ground, but remained conscious. He was able to get up on his own and walk to the sideline to be evaluated by the athletic training staff.

INITIAL EVALUATION

SIGNS AND SYMPTOMS: c/o tinnitus, nausea, slight dizziness, and a headache.

OBSERVATION: An epistaxis developed secondary to the trauma. No obvious deformities of the face were visible.

PALPATION: Initial palpation of facial bones and structures appeared to be WNL. Some soreness was noted with palpation in the region inferior to the right orbit. Intra-oral palpation and TMJ palpation were pain free.

RANGE OF MOTION: Cervical and TMJ ROM were WNL; however, increased pain was present in the right zygomatic region when the athlete was asked to bite down.

SPECIAL TESTS: Vital signs were taken and concluded to be of normal values. Cranial nerves, myotomes, and dermatomes were also tested and were WNL. In addition, no significant problems with vision were present.

As the evaluation was being conducted, a large nodule of swelling, as well as ecchymosis, had begun to form below the right orbit.

TREATMENT

The initial treatment consisted of controlling the bleeding and applying ice to the orbital region. The athlete was then brought to the ATR to be monitored. Vital signs were taken periodically.

CHANGES IN THE ATHLETE'S CONDITION

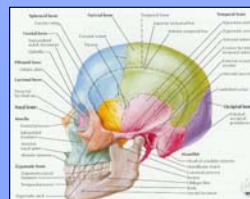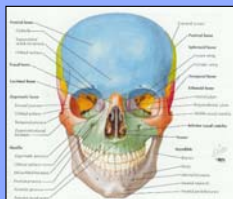
As time progressed, the athlete became disoriented and was c/o progressively worsening concussive symptoms, including: a headache, nausea, dizziness, and drowsiness. In addition, he began acting "out of character" (quieter than usual), and expressed a desire to go to sleep.

Further medical attention was rendered necessary, and the athlete was taken to the ER.

DIFFERENTIAL DIAGNOSIS

The differential diagnosis at this time included a concussion, contusion, or fracture of a facial or nasal bone.

BONES OF THE FACE AND SKULL

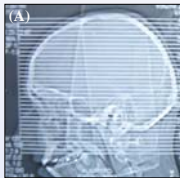


DIAGNOSTIC TESTING

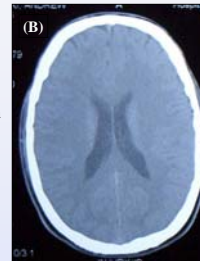
At the Emergency Room, the athlete underwent diagnostic testing which included General Radiography and Computed Tomography.

X-RAYS: Anterior/Posterior, Lateral, and Odontoid View Radiographs were taken. All of the images came back negative, ruling out any involvement of the cervical vertebrae.

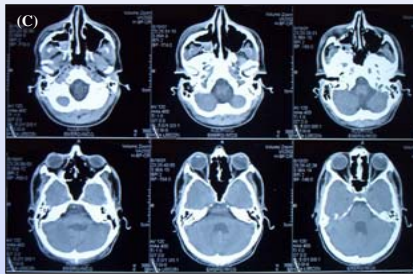
CT SCANS: Axial Window Levels (A)



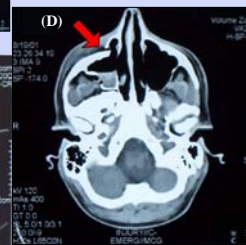(B) Lateral Ventricles. The white is the cranium, verifying no skull fx.. No signs of intracranial hemorrhage are present. A darkened area on the outer aspect of the cortex, often in conjunction with a displacement of the ventricles, would be indicative of a subdural hematoma →



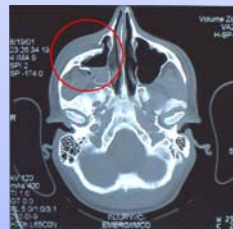← (C) Axial progression



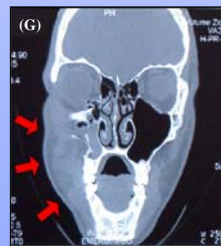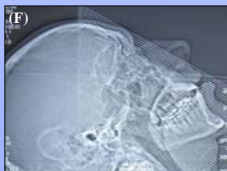(D) The fracture of the inferior orbital rim is evident. (enlargement of window level 174 from the axial progression) ↴



(E) The fluid-air level in the maxillary sinus is visible. Superficial swelling over the right side of the face can be seen. The presence of this makes the cheeks appear to be at the same level bilaterally. ↴



Coronal Window Levels (F)



(G) Fluid filled maxillary sinus. Soft tissue distortion of the right cheek due to edema can be fully appreciated when compared to the smooth contour of the left side of the face. ↴

CLINICAL COURSE

The athlete was deemed stable and released from the ER. Per MD orders he was to be monitored daily for any changes in s/s and was to schedule an appointment with a facial plastic surgeon.

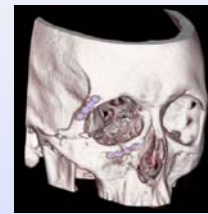
Two days post injury: MD Appointments

Ophthalmologist: cleared that there was no entrapment or diplopia.

Facial Plastic Surgeon: made arrangements to proceed with surgical intervention.

By this time, the swelling had subsided significantly, however, ecchymosis was present around the right orbit and a depression of the right tripod area was visible and palpable. Tenderness and paresthesia were also noted over this region.

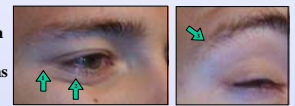
SURGICAL INTERVENTION



Ten days post injury: ORIF

The athlete underwent an open reduction and internal fixation of the right tripod fracture, in which plating was used to repair the fracture.

The location of the incisions ↴



DISPOSITION S/P

1 week: follow-up MD appointment, healing occurring normally.

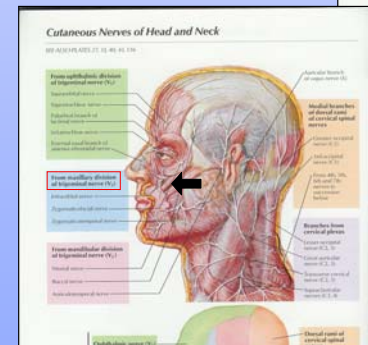
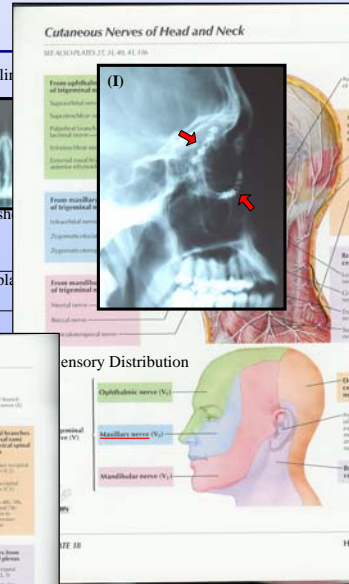
3 weeks: running as tolerated

5 weeks: light weight training

8 weeks: returned to full play

2 years: athlete reports permanent diminish sensation over his right cheek.

• General Radiographs showing surgical plating (H) Waters View, (I) Lateral View.

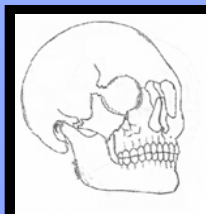


WHAT MAKES THIS CASE UNIQUE?

Mechanism: It is rather uncommon to see tripod fractures in athletics. Such fractures are more commonly seen in acute traumatic accidents such as MVAs, where the individual was not wearing a seat belt and the fracture occurs due to the intense force present when the victim's face comes in contact with the dashboard. In addition, tripod fractures, are sometimes sustained in bar room brawls in which a bar stool, or other inanimate object, is the weapon of choice.

Signs and Symptoms: Although the athlete had sustained a significant amount of trauma, he had displayed a minimal physical response. Common s/s of a tripod fx include: significant pain, step deformity, and sometimes numbness over the cheek. Significant amounts of swelling will be present, but may or may not be immediately noticeable depending on the degree of posterior displacement of the fracture site.

FINAL DIAGNOSIS



RIGHT TRIPOD FRACTURE

A tripod fracture includes a fracture of the:

- Inferior Orbital Rim
- Lateral Orbital Rim
- Zygomatic Arch

